

*Review Article*

# A Technique Redefined for the Prosthodontic Rehabilitation of Completely Edentulous OSMF Patient; A Case Report

Akanksha Katkade<sup>1,\*</sup>, Shankar Dange<sup>2</sup>, Kishor Mahale<sup>3</sup> and Smita Khalikar<sup>4</sup>

<sup>1</sup>Post graduate student, Department of Prosthodontics, Government dental College and hospital, Navkhanda, Chhatrapati Sambhajinagar (Aurangabad), Maharashtra- 431001, India.

<sup>2,3,4</sup>Professor, Department of Prosthodontics, Government dental College and hospital, Navkhanda, Chhatrapati Sambhajinagar (Aurangabad), Maharashtra- 431001, India.

\*Corresponding Author Email Address: [enf.akanksha97@gmail.com](mailto:enf.akanksha97@gmail.com)

DOI: <https://doi.org/10.69996/ijari.2023008>

## Article Info

Received 16 September 2023

Revised 8 October 2023

Accepted 20 October 2023

Published 31 December 2023

## Keywords

OSMF, Microstomia, Impression, Complete Denture, Cross Arch Arrangement

## ABSTRACT

When a patient needs a tooth extracted and replaced, prosthodontics is the area of dentistry that focuses on restoring both function and aesthetics. However, microstomia patients face difficulties throughout the therapy process. Therefore, traditional denture manufacture is not enough for the treatment of these individuals. This clinical case study details the process of making a full denture using new impression methods and a revised methodology for the placement of the teeth

## 1. Introduction

One of the most prevalent behaviors in India that might cause a variety of oral cavity pathologies is chewing betel nuts. The development of OSMF, which can lead to microstomia, is a prevalent premalignant disease.

As a sneaky, long-term condition, submucous fibrosis can impact the pharynx as well as any area of the mouth. This condition is always accompanied by a juxta-epithelial inflammatory reaction, a fibroelastic change of the lamina propria, and epithelial atrophy, which causes stiffness of the oral mucosa, trismus, and the inability to eat. Vesicle formation may occasionally precede or be associated with it. (Old Town) (1)

A disorder known as microstomia can be either inherited or developed over time, and it is characterized by a narrowing of the mouth's opening or an unusually small mouth cavity (2).

Microstomia can also develop as a result of cleft lip, radiation to the head and neck, orofacial burns, scleroderma, reconstructive lip procedures, trauma, or fibrosis of the masticatory muscles.

Patients with microstomia can benefit from prosthodontic treatment in a number of ways, and there are a plethora of devices available to widen the mouth's commissure [4-6]. Using polyether elastic impression material and the minimal pressure technique, conventional full dentures for OSMF patients were described by Watanabe et al. [7] and Sonune and Dange [8]. Using a plastic stock tray and press button attachments, Shivasakthy and Asharaf Ali [9] modified the technique of primary impression. To get more detail, Whitsitt and Battle used light body silicone to wash putty silicone, which served as a flexible tray, for primary impressions of dentulous arches. Metal sleeves and two die pins were detailed by Bachhav and Aras [10] as the method for creating the final impression. In their description of the OSMF patient's

fabrication process, Caculo et al. detailed the sectional custom tray for the maxilla.

The aforementioned methods of microstomia patient rehabilitation were laborious, costly, and time-consuming [11-14]. Accordingly, the case report details a straightforward adjustment to the standard process for taking impressions and arranging teeth [15-17].

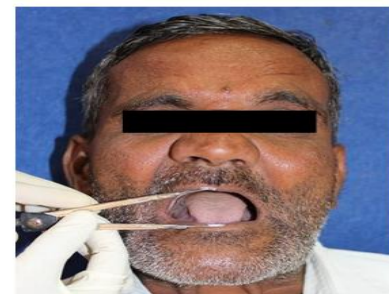## 2. Case Report

A 45-year-old male patient presented to the prosthodontics department at the Government Dental College and Hospital in Aurangabad complaining of difficulty chewing, limited opening of the mouth, speech impairment, and an unattractive appearance.

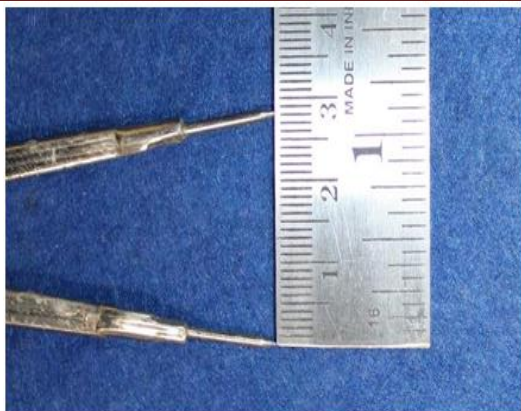Opening the mouth is not as easy as previously thought, according to the extraoral exam. Denture creation using traditional methods will thus be challenging; hence, this clinical report describes a modified procedure.

### Extraoral Examination –

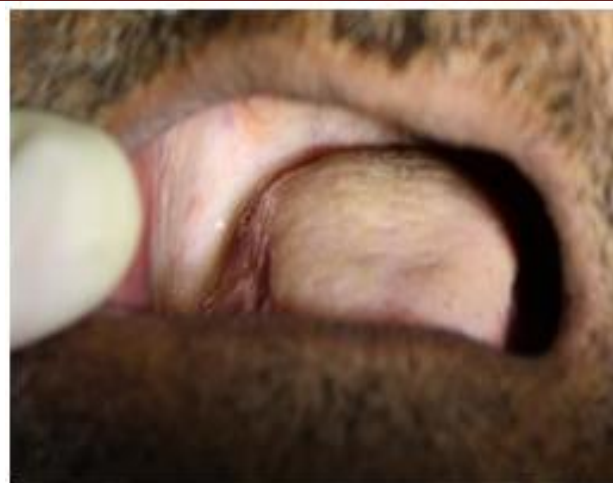- Reduced mouth opening = 27 mm and Angular cheilitis Figure 1,2 showing Reduced mouth opening, Measurements



**Figure 1.** Reduced mouth opening



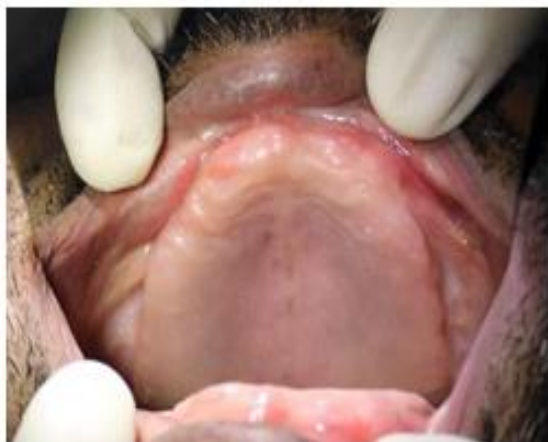**Figure 2. Measurements**



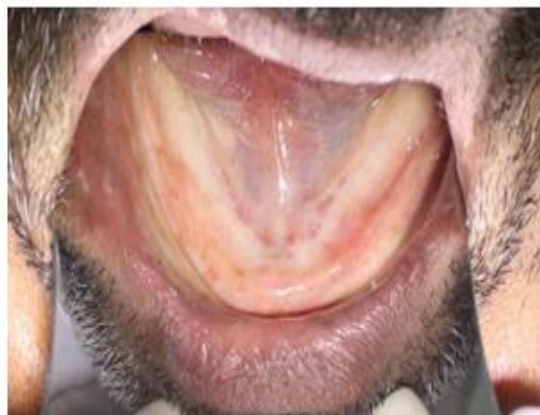**Figure 5. Palpable fibrous bands**

#### Intraoral Examination –

- The mandibular and maxillary arches are devoid of any teeth.
- A shallow buccal vestibule with atrophic mucosa and a severely resorbed mandibular arch with destroyed buccal and lingual vestibule are the results of the resorbed flat and depressed edentulous maxillary alveolar ridge, which is connected to the alveolar ridge by fibers that stretch from the buccal mucosa.
- Two sides of the buccal mucosa with palpable fibrous bands that extend to the soft palate. figure 3,4,5 showing Maxillary arch, Mandibular Arch, Palpable fibrous bands



**Figure 3. Maxillary arch**



**Figure 4. Mandibular Arch**

#### 3. Treatment Plan

1. A small-sized stock tray (one tray) was used to make an initial imprint of the maxillary and mandibular arches using impression compound.
2. Specialized trays made, and method adjusted for creating last impressions

##### For maxillary arch

-The patient's mouth was prepared for a single-step impression without border molding after the tray was adjusted. Condensation silicone putty was then mixed and loaded onto the tray.

-Light-body condensation silicone impression material was used to make the wash impression

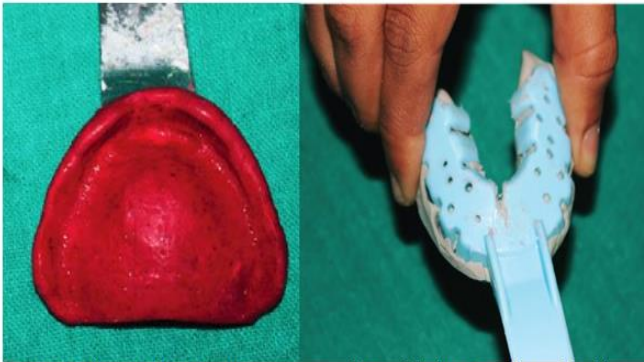
##### For Mandibular arch

-The border molding was done utilizing the all green imprint technique. Then, the light body condensation silicone substance was utilized to make a wash impression

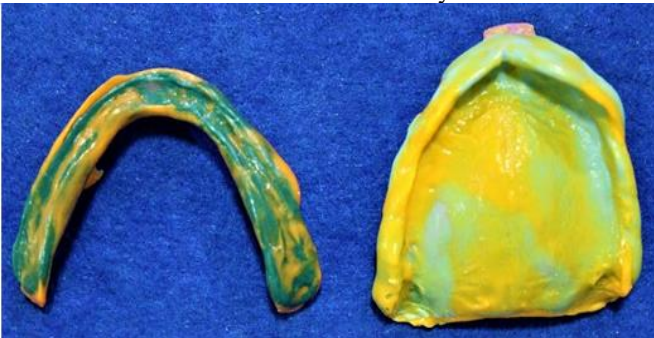3. Recording of maxillomandibular connection.
4. Third, the mandibular arch and the maxillary arch are undergoing centrifugal and centripetal resorption, respectively, leading to a cross bite.
5. A cross-bite relationship was achieved with the use of Acry-rock teeth set (mold no. 13), and the try-in was successfully completed.
6. Five, the traditional method of denture construction is carried out utilizing Acrypol heat cure denture base resin.
7. Denture implantation follows any required modifications.
8. The stability and retention of the maxillary denture were satisfactory, while the mandibular denture was stable but had poor retention.
9. Eighth, lower denture adhesives should be used.
10. Check-ins every day, every month, every three months, every six months, and every year.
11. Wearing the denture brought considerable satisfaction to the patient, who reported no discomfort or irritation.

Figures 6,7,8,9,10,11,12 showing Maxillary Preliminary impression and Mandibular PI made in flexible tray, Maxillary FI made using C silicone impression material single step without border molding, Maxillomandibular

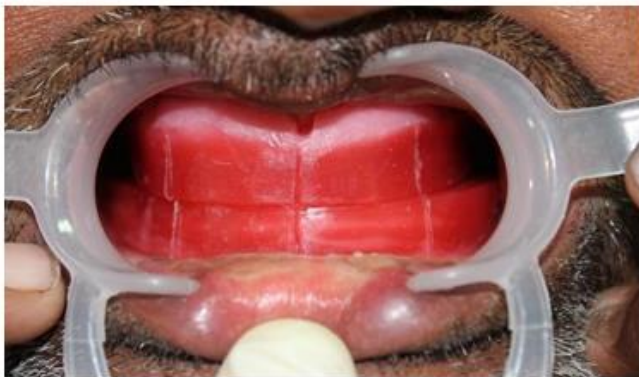relationship, Cross arch teeth arrangement, Pre operative, Postoperative, Finished polished Final denture intraorally



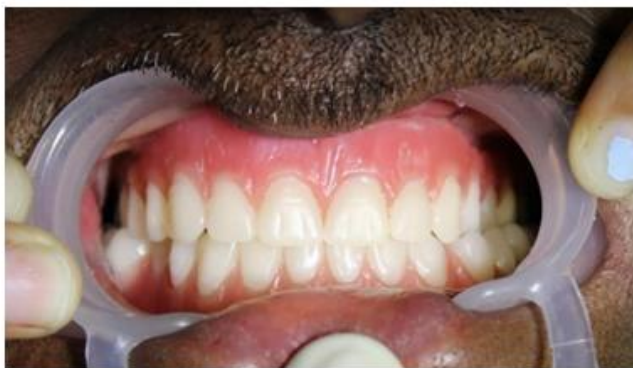**Figure 6.** Maxillary Preliminary impression and Mandibular PI made in flexible tray



**Figure 7.** Maxillary FI made using C silicone impression material single step without border molding



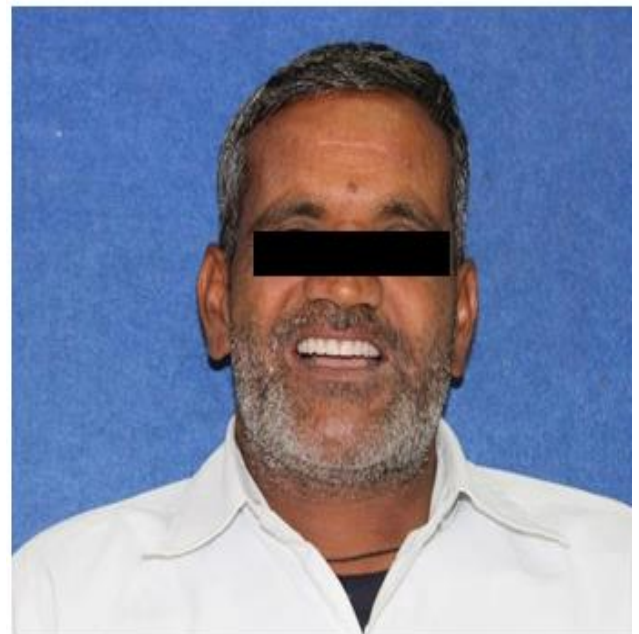
**Figure 8.** Maxillomandibular relationship



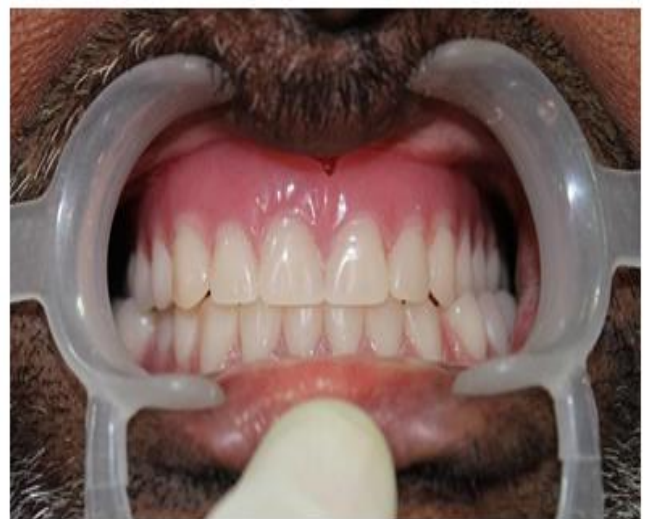**Figure 9.** Cross arch teeth arrangement



**Figure 10.** Pre operative



**Figure 11.** Postoperative



**Figure 12.** Finished polished Final denture intraorally

#### 4. Discussions

When it comes to keeping dentures in place, nothing matters more than active muscles. Complete denture fabrication benefits from the neutral zone concept in cases of damaged and wide mandibular alveolar ridges caused by extensive bone resorption from long-term edentulousness. There is no need to record the neutral zone separately because of the low muscle activity here caused by the stiffness. The rims should be shaped appropriately during jaw relation to neutralize buccolingual forces. The artificial teeth should be arranged precisely over the residual ridge in the neutral area, which improves the denture's stability and increases the patient's comfort. (13) The self-perceived pleasure with complete dentures with lingualized or anatomic posterior occlusal surfaces was higher than that of nonanatomic posterior occlusal teeth, according to McCord.

The cross-arch arrangement of the back teeth is recommended in cases when the anomaly is more severe, such as when the mandibular arch is significantly broader than the maxillary arch (14). The back teeth of the upper jaw may be found on the left side of the jaw, whereas the back teeth of the lower jaw can be found on the right side of the jaw. The phrase "cross arch arrangement" comes from the fact that this form of arrangement involves a change to both the arch and the side of the teeth (14).

Rehabilitating patients with microstomia has been covered by numerous authors in the past. However, the patient had a hard time wearing the complicated prosthesis, the procedures were expensive, and they necessitated further laboratory testing. In order to circumvent these drawbacks, we have employed a slightly altered traditional imprint process in conjunction with an alternative approach for tooth arrangement. To achieve a minimum 5 mm improvement in mouth opening, we can employ pre-prosthetic therapy measures such medication and exercises. Thanks to this improvement, inserting the No. 0 stock tray into patients' mouths is now easier. For this reason, we can also utilize flexible trays.

In order to avoid the necessity for segmented, hinged trays for subsequent procedures, we can create custom trays from the primary cast that can be readily put into the patient's mouth.

This case report details a straightforward prosthodontic method that is simple, modifiable, inexpensive, and uncomplicated.

#### 5. Conclusions

The manufacturing of the prosthesis becomes more challenging when the mouth opening is smaller than the standard range of 35-40mm. The main benefits, according to this clinical research, include the ease of manufacturing, the utilization of a modified impression process, and a tooth arrangement protocol. Without the need for complex apparatus or attachment devices, this procedure can be utilized in routine dental treatment. Time, labor, and material savings are achieved with this method, which is a drawback shared by all sectional tray/prosthesis configurations.

Therefore, this is a novel and easy method for microstomia patients to rehabilitate, and they will need to come in for very few follow-up appointments.

**Acknowledgment:** Not Applicable.

**Funding Statement:** The author(s) received no specific funding for this study.

**Conflicts of Interest:** The authors declare no conflicts of interest to report regarding the present study

#### References

- [1] Pindborg and Sirsat, "Oral submucous fibrosis," *O.S., O.M. & O.P.*, 22, 1996.
- [2] K. Vinayagavel, C. Sabarigirinathan, G. Sri Rama Prabu, Anshul Choubey and K.T. Jeyanthi, "Prosthodontic Management of Oral Submucous Fibrosis," *IJSRR*, 3(2), 2014, 205 – 211.
- [3] J. F. McCord, K. W. Tyson and I. S. Blair, "A sectional complete denture for a patient with microstomia," *J Prosthet Dent*, 61, 1989, 645-7.
- [4] B. K. Moghadam, "Preliminary impression in patients with microstomia," *J Prosthet Dent*, 67, 1992, 23-5.
- [5] J. A. Whitsitt and L. W. Battle, "Technique for making flexible impression trays for the microstomic patient," *J Prosthet Dent*, 52, 1984, 608-9.
- [6] Y. Suzuki, M. Abe, T. Hosoi and K.S. Kurtz, "Sectional collapsed denture for a partially edentulous patient with microstomia: A clinical report," *J Prosthet Dent*, 84, 2020, 256-9.
- [7] I. Watanabe, Y. Tanaka, C. Ohkubo and A.W.Miller, "Application of cast magnetic attachments to sectional complete dentures for a patient with microstomia: A clinical report," *J Prosthet Dent*, 88, 2002, 573-7.
- [8] S. J. Sonune and S. P. Dange, "Oral submucous fibrosis recuperated with prosthodontic approach — A case report," *J Dent Med Sci*, 3, 2012, 19-21.
- [9] M. Shivasakthy and S. Asharaf Ali, "Customized sectional stock tray for a patient with a restricted oral opening," *J Clin Diagn Res*, 5, 2011, 1686-7.
- [10] V. C. Bachhav and M. A. Aras, "A simple method for fabricating custom sectional impression trays for making definitive impressions in patients with microstomia," *Eur J Dent*, 6, 2012, 244-7.
- [11] N. R. Rao, "Oral submucous fibrosis: a contemporary narrative review with a proposed interprofessional approach for an early diagnosis and clinical management," *Journal of Otolaryngology - Head and Neck Surgery* 49, 2020, 3.
- [12] T. R. Yoithappabhunath, "Pathogenesis and therapeutic intervention of oral submucous fibrosis," *J Pharm Bioall Sci*, 5, 2013, 85-8.
- [13] D. R. Cagna, J. J. Massad and F. J. Schiesser, "The neutral zone revisited: From historical concepts to modern application," *J Prosthet Dent*, 101, 2009, 405–12.
- [14] Abhijit Tambe, Sanjayagouda B Patil, Sudhakara Bhat, and Mokshada M Badadare, "Cross-arch arrangement in complete denture prosthesis to manage an edentulous patient with oral submucous fibrosis and abnormal jaw relation," *BMJ Case Rep*, 2014.

- [15] S. Patil, S. C. Sarode, G. S. Sarode, S. Bhandi, K. H. Awan and M. Ferrari, "Prosthetic rehabilitation of oral submucous fibrosis patients: A systematic review of published case reports and case series," *PLoS ONE*, 12(9), 2017, e0184041.
- [16] M. M. Ibrahim, V. Rangarajan, P. B. Yogesh, M. A. Riyaz and T. Selvakumar, "Prosthodontic rehabilitation of an edentulous patient affected with oral submucous fibrosis - A clinical report," *SRM J Res Dent Sci* 3, 2012, 152- 154.
- [17] M. Kajave, S. Shingote, R. Mankude and K. Chodankar, "An innovative prosthodontic approach in managing oral submucous fibrosis patient," *SRM J Res Dent Sci*, 6, 2015, 139-43.